

Case Report

Advanced Heterotopic Pregnancy: A Case Report

Dehayni Mohamed^{1,2,3}, Moussaoui Driss^{1,3}, Kouach Jaouad^{1,3}

¹Department of Gynecology-Obstetric, Military Training Hospital Med V, Rabat, Morocco

²Department of Gynecology-Obstetric and Surgery, Military Training Hospital Med V, Rabat, Morocco

³Faculty of Medicine and Pharmacy, University Mohammed V Souissi, Rabat, Morocco

Email address:

mohamedehayni@gmail.com (D. Mohamed), moussaouidriss@yahoo.fr (M. Driss), kouach_jaouad@yahoo.fr (K. Jaouad)

To cite this article:

Dehayni Mohamed, Moussaoui Driss, Kouach Jaouad. Advanced Heterotopic Pregnancy: A Case Report. *Journal of Gynecology and Obstetrics*. Vol. 5, No. 1, 2017, pp. 9-19. doi: 10.11648/j.jgo.20170501.12

Received: December 15, 2016; **Accepted:** December 29, 2016; **Published:** February 17, 2017

Abstract: Heterotopic pregnancy is a pathological form of biovular dizygotic twin pregnancy. This is a rare disease, but its incidence has increased sharply in recent years due to the development of medically assisted procreation and the resurgence of pelvic infections. Diagnosis and therapeutic management of heterotopic pregnancy are essential to improve maternal prognosis and proper conduct of the intrauterine pregnancy. The authors report a new advanced heterotopic pregnancy in a woman treated for infertility. Through the literature data, they focus on the different aspects of this rare form of pregnancy.

Keywords: Pregnancy, Ectopic Pregnancy, Pregnancy Heterotopic, Ultrasound, Laparoscopy

1. Introduction

Heterotopic pregnancy is the simultaneous coexistence of an intrauterine pregnancy (IUP) and an ectopic pregnancy (EP) in the same patient, regardless of the location of the ectopic pregnancy [1, 2, 3]. It is a pathological and exceptional form of biovulardizygote twin pregnancy. The ectopic pregnancy can sometimes evolve beyond the 4th month in the form of abdominal pregnancy. This latter form has rarely been described in the literature [2, 4]. The authors report a new case of heterotopic pregnancy with abdominal localization, followed from 18 weeks of gestation. Through the literature data, they discuss diagnostic modalities, criteria allowing conservative management, procedures for monitoring these pregnancies and finally the terms of delivery.

2. Observation

Mrs. YM, 27 year-old primigravida woman, consulted in our service at 18 weeks of gestation for a heterotopic pregnancy diagnosed in a private clinic facility. In her medical history, there was a peritoneal tuberculosis diagnosed during laparoscopy for infertility evaluation in 2010. The woman underwent tuberculosis treatment for six months according to

the Moroccan national tuberculosis program. She had a regular cycle, no contraception and was treated for primary infertility for 10 years. She received in vitro fertilization with transfer of two embryos on March 29, 2013. The first ultrasound at 7 weeks of gestation for minimal bleeding showed a progressive intrauterine pregnancy with detachment trophoblast, and the patient was treated by progesterone with positive results. Ultrasound control at 10 weeks of gestation showed a single scalable intrauterine pregnancy with regression of trophoblastic release.

Clinically, the woman was asymptomatic. At 15 weeks, ultrasound showed two ongoing pregnancies, one intrauterine and the other ectopic, located in the Douglas pouch (figure 1 to 7). The patient consulted in our department of Gynecology-Obstetrics, Military Hospital Mohamed V of Rabat at 18 weeks of gestation. Physical examination found the patient in otherwise good general condition, without any problematic signs except for functional constipation. The fundal height was 20 cm. The vaginal examination showed a filled Douglas. The rest of the physical examination was normal. The trans-abdominal ultrasound and 3.5 MHZ endovaginal confirmed the diagnosis of one heterotopic pregnancy with another fault-free intrauterine pregnancy with the placenta inserted on the posterior uterine wall. The ectopic pregnancy was retro-uterine. The fetus was surrounded by a

gestational sac and the placenta was localized on the posterior uterine wall.

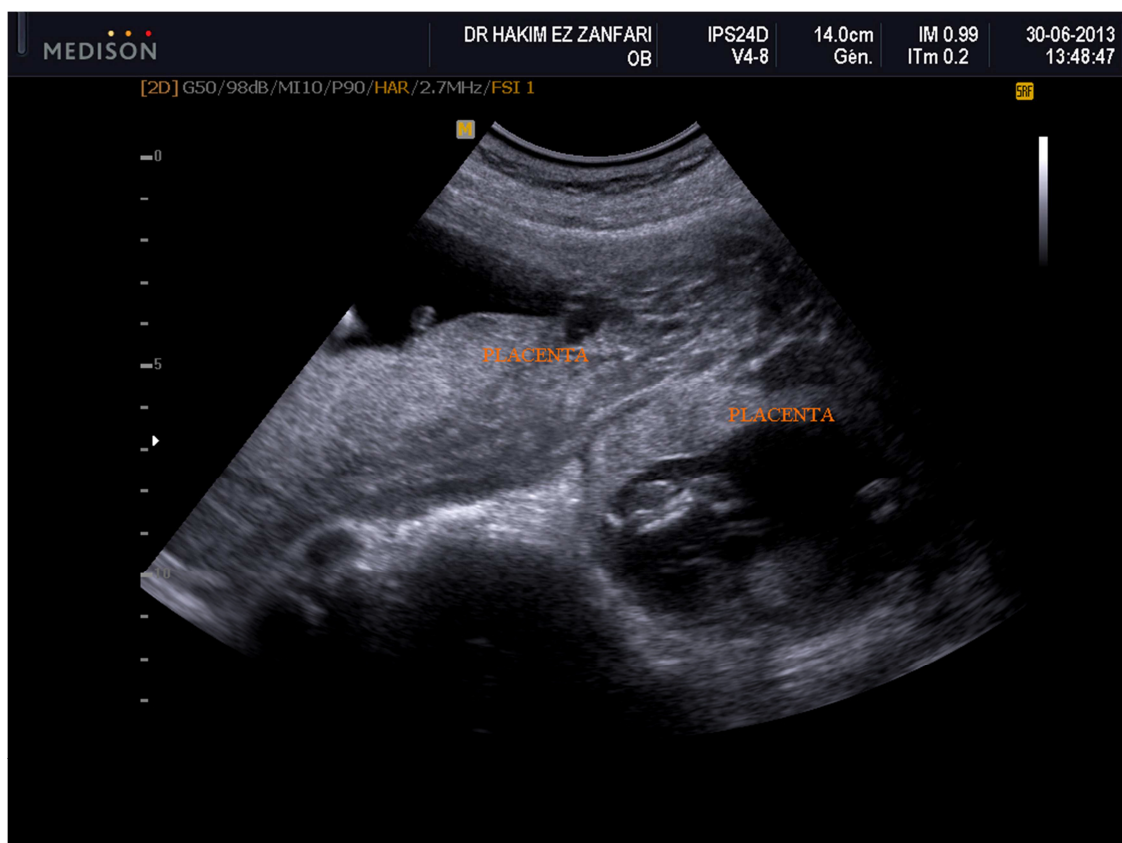

Figure 1. Transabdominal ultrasound at 15 weeks of gestation showing 2 fetus (the first one is intrauterine and the second one is abdominal) with two placenta.

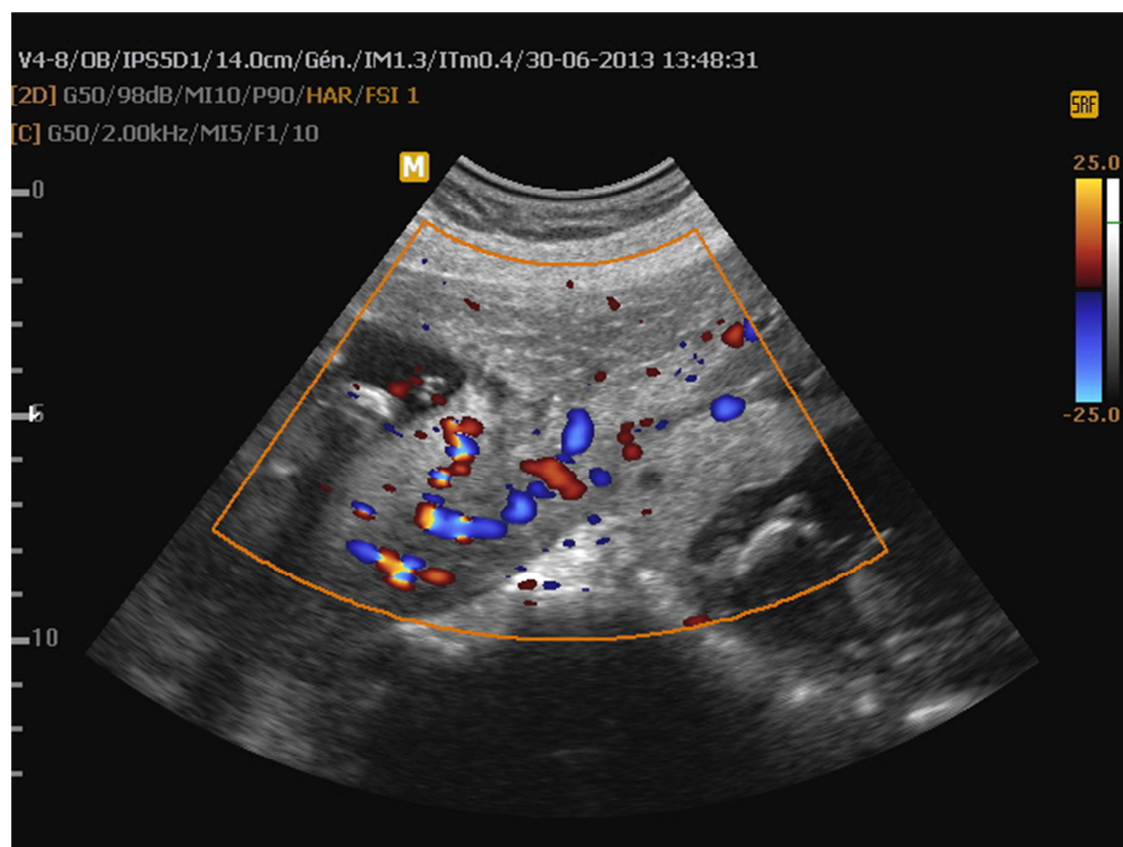


Figure 2. Transabdominal ultrasound at 15 weeks of gestation showing 2 fetus (the first one is intrauterine and the second one is abdominal) with two placenta.

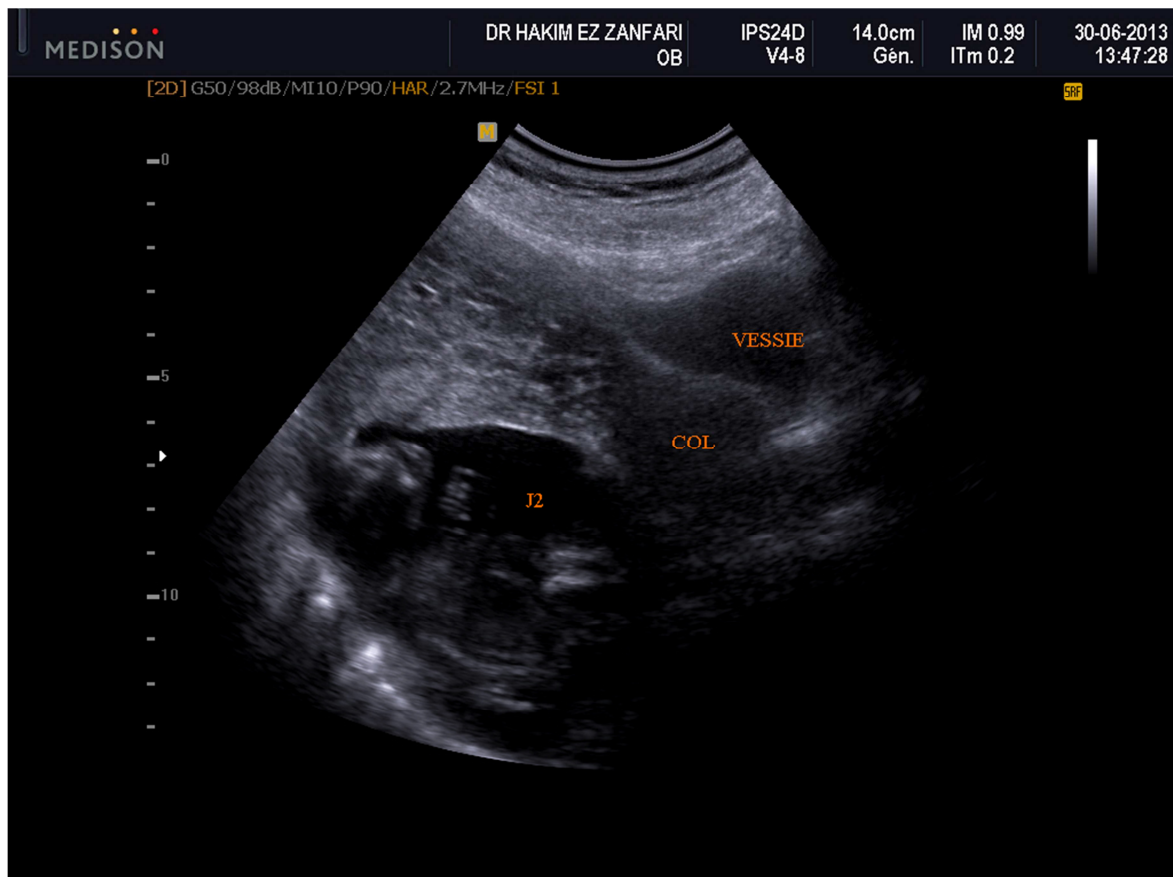


Figure 3. Transabdominal ultrasound at 15 weeks of gestation showing 2 fetus (the first one is intrauterine and the second one is abdominal) with two placenta.

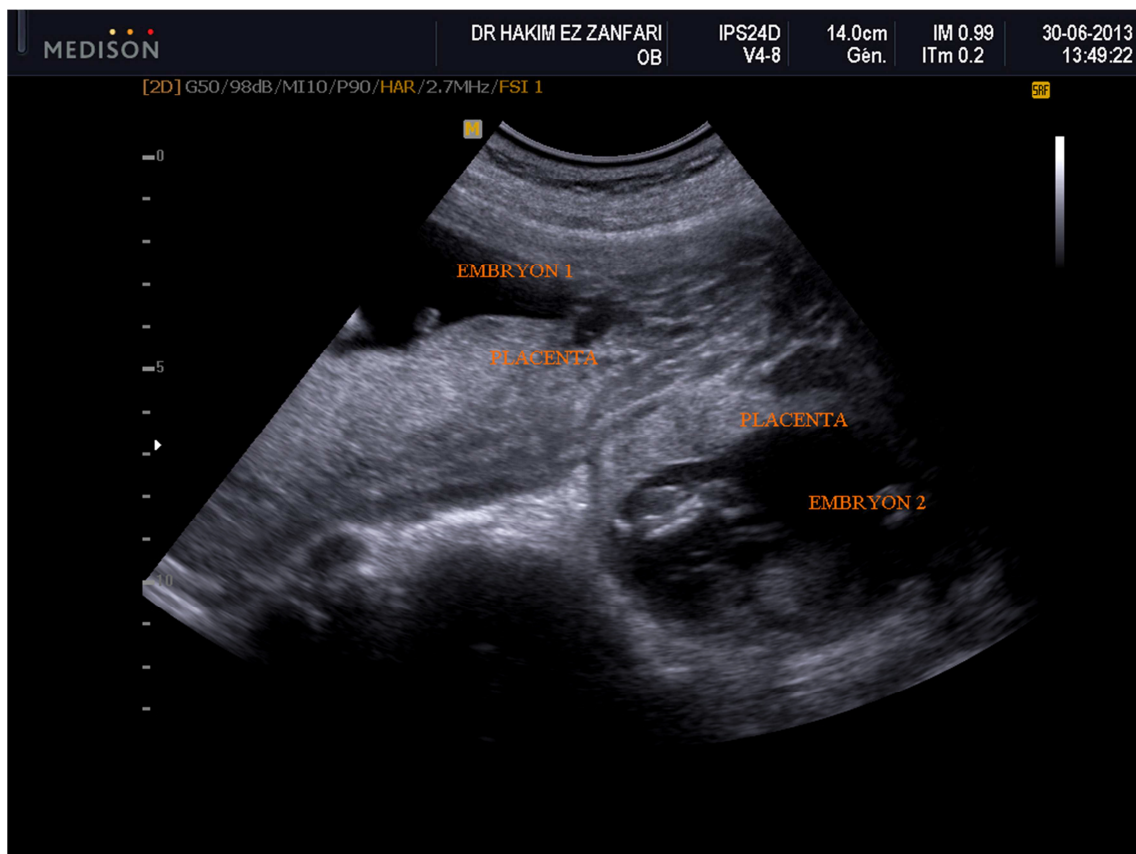


Figure 4. Transabdominal ultrasound at 15 weeks of gestation showing 2 fetus (the first one is intrauterine and the second one is abdominal) with two placenta.

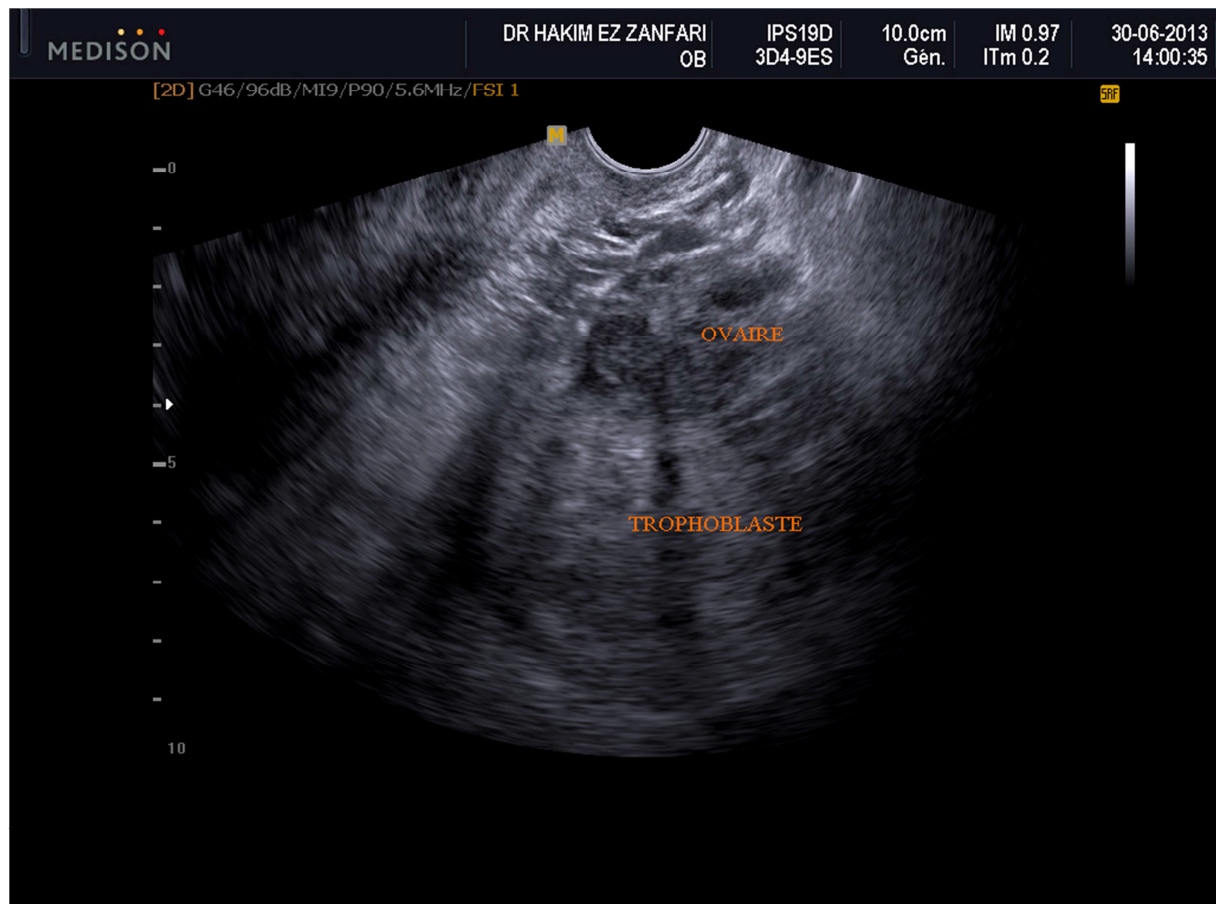


Figure 5. Transabdominal ultrasound at 15 weeks of gestation showing 2 fetus (the first one is intrauterine and the second one is abdominal) with two placenta.

Comparaison foetale	foetus A	foetus B	foetus C	foetus D
A.G. moyen	15s0j	15s6j		js
DEA par Moy. A.G.	22-12-2013	16-12-2013		
Comparaison biométrique	foetus A	foetus B	foetus C	foetus D
LCC		82.82		mm
BIP	30.83(15s0j)	34.04(15s6j)		mm
PC	117.03	124.45(16s2j)		mm
FEM	16.77(15s0j)	17.62(15s2j)		mm

Figure 6. Biometry of the fetus: fetus A (intra uterine), fetus B (abdominal localization).

Abdominal and pelvic MRIs were performed at 19 weeks of gestation. It confirmed the ultrasound data, especially in relation to the placenta and the pelvic organs. The placenta was on the posterior wall of the uterus and the left broad ligament (Figure 7 to 9).

The woman was informed about the risks of the development of such a pregnancy and the possibility of intervention at any gestational age. After multidisciplinary discussions, including with anesthetists and neonatologists, and after the informed consent of the couple was established, the physicians decided to closely follow the double pregnancy until birth. The prenatal diagnosis allowed the diagnosis of gestational diabetes at 22 weeks of gestation. The diabetes was balanced with insulin. Morphological obstetric ultrasound

showed a biometrics matching gestational age without abnormalities. The Intra-abdominal fetal head was wedged in the Douglas pouch and had an appearance of dolichocephaly. The Continuation of pregnancy was marked by the occurrence of self-limiting sub-occlusive episodes. Fetal active movements were perceived painless. The team found good ultrasound fetal growth. Changes during pregnancy showed no abnormalities, including no signs of impact of gestational diabetes on either fetus. At 32 weeks of gestation, the ultrasound monitoring noted growth retardation of the intra-abdominal fetus with decreased amniotic fluid. The umbilical and cerebral Doppler were both normal. Intrauterine fetal biometry was also normal; the amniotic fluid was sufficient and without Doppler abnormalities.

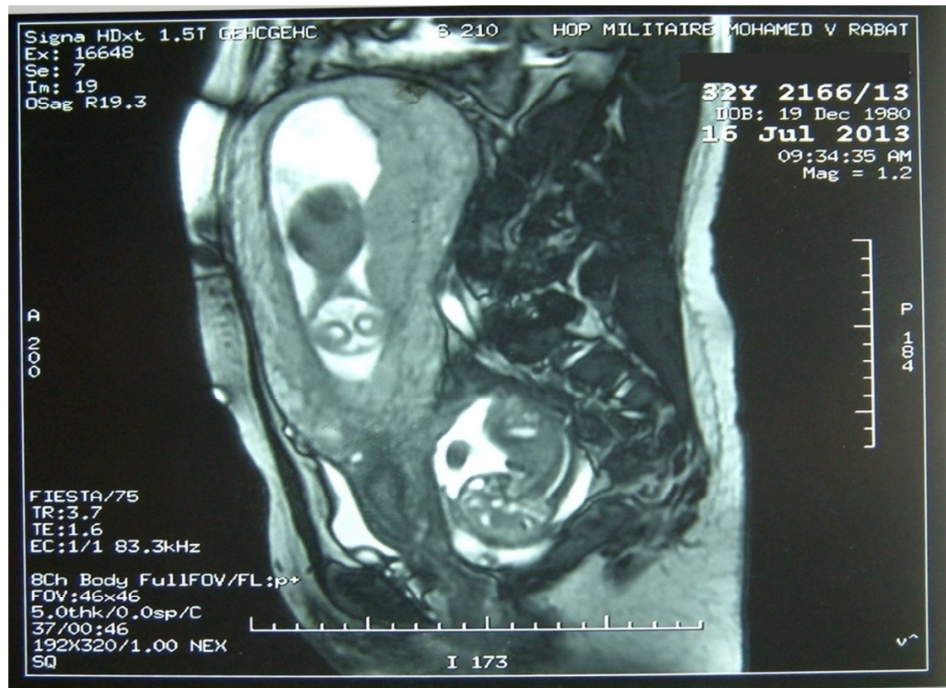

Figure 7. Pelvic MRI at 19 weeks of gestation showing an intrauterine pregnancy and the ectopic pregnancy with the relation between the placenta and the pelvic organs.

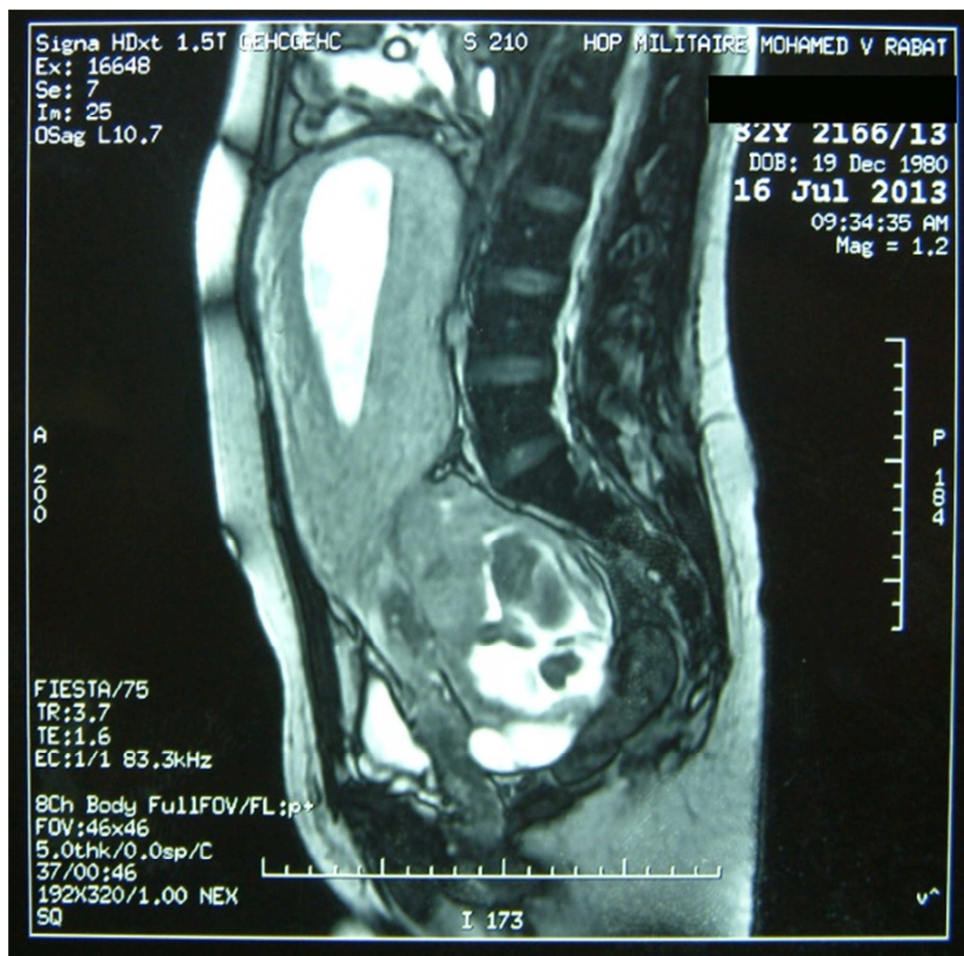

Figure 8. Pelvic MRI at 19 weeks of gestation showing an intrauterine pregnancy and the ectopic pregnancy with the relation between the placenta and the pelvic organs.

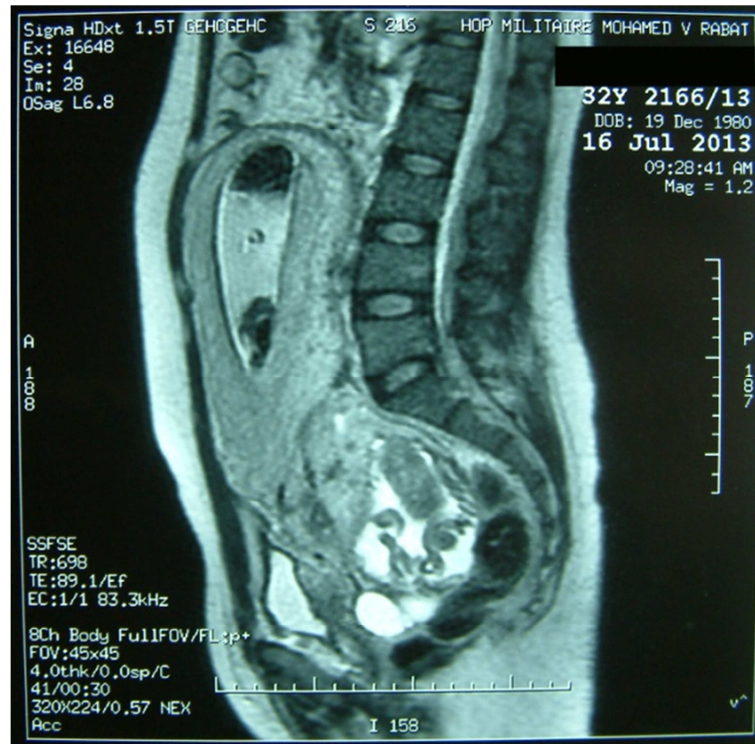

Figure 9. Pelvic MRI at 19 weeks of gestation showing an intrauterine pregnancy and the ectopic pregnancy with the relation between the placenta and the pelvic organs.

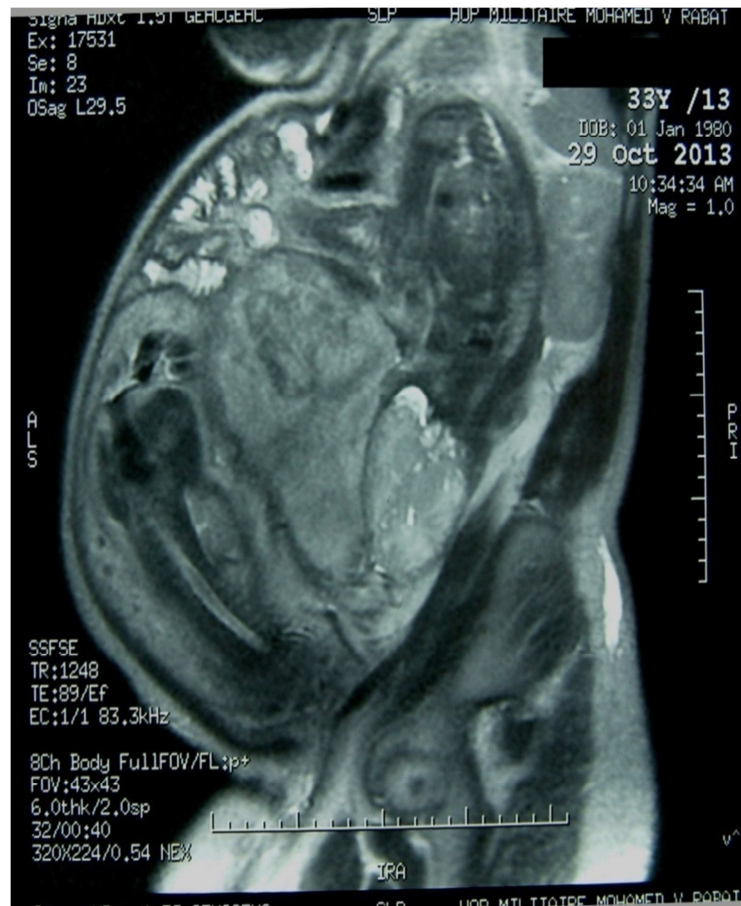

Figure 10. Pelvic MRI at 32 weeks of gestation.

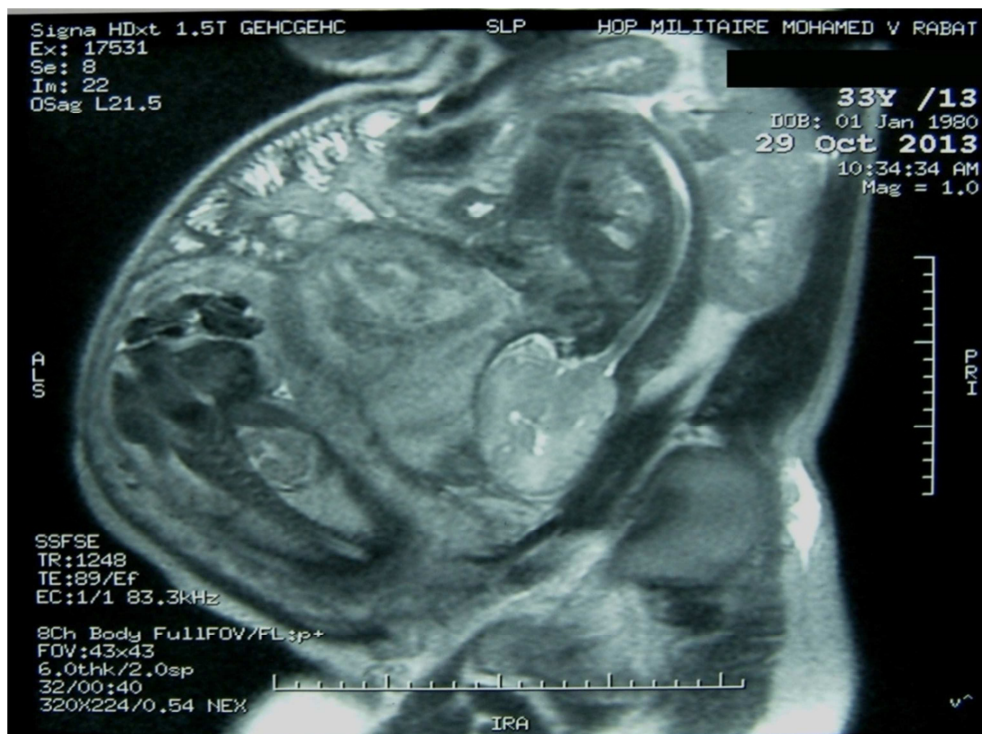


Figure 11. Pelvic MRI at 32 weeks of gestation.

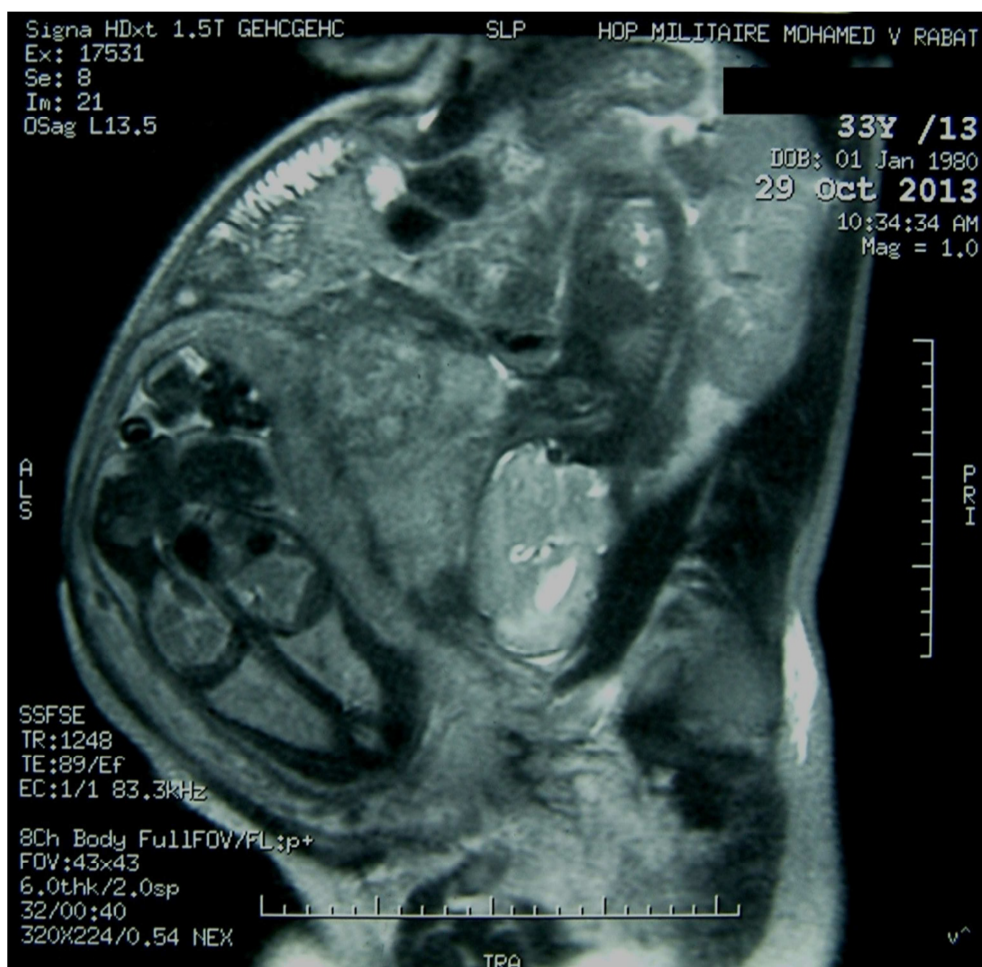


Figure 12. Pelvic MRI at 32 weeks of gestation.

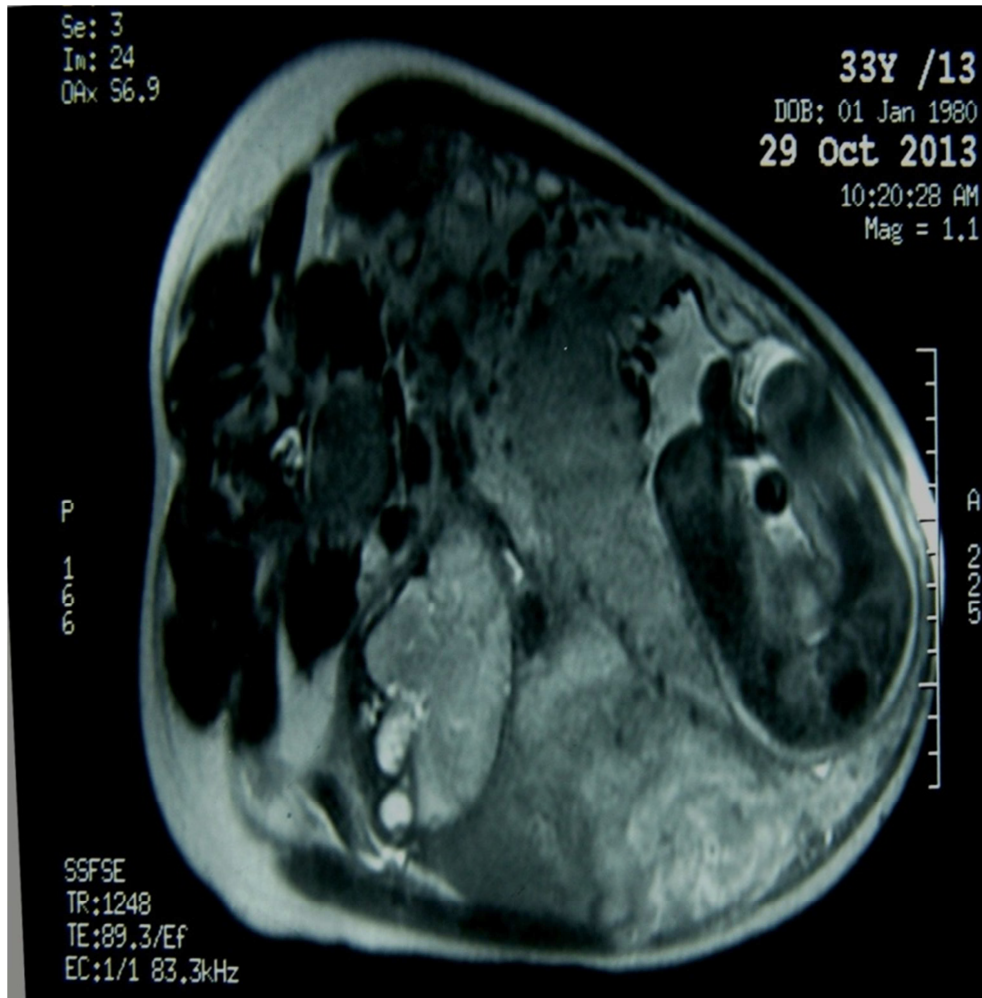


Figure 13. Pelvic MRI at 32 weeks of gestation.

Ultrasound monitoring showed stagnation in the growth of intra-abdominal fetus with decreased amniotic fluid. Laparotomy was scheduled at 34 weeks with a multidisciplinary team within a specific anesthetic protocol adapted to the pre-and post-operative bleeding risk. The midline laparotomy astride the umbilicus was performed. The transverse segmental hysterotomy gave birth to a girl weighing 2250 g, Apgar 10/10. The rest of exploration found that the second pregnancy was established on the rear face of the uterus and left broad ligament (figure 14). The rest of the amniotic cavity was inserted on the omentum. The water breaking allowed the extraction of a boy weighing 1400g, Apgar 10/10. After cord clamping, delivery and digital scissors proved colitis. The insertion areas in the uterus and left broad ligament were padded. The remainder of the membranes were removed with selective hemostatic ligatures.

Hemostasis was assured. Drains were placed in the peritoneal cavity. Blood loss was compensated; intraoperative and postoperative transfusion of concentrated globular 7 6 7 platelet concentrates and new frozen plasma. Intestinal transit resumed in 72 hours. The examination of newborns, showed no abnormalities in the fetus of intrauterine pregnancy. However, the second twin had dolichocephaly related to the constant bad positioning in the Douglas pouch, respiratory

discomfort, probably due to pulmonary hypoplasia, requiring supplemental oxygen continuously. The patient was discharged on day 6 with the first twin, while the second died at Day 9 in a state of severe respiratory distress.

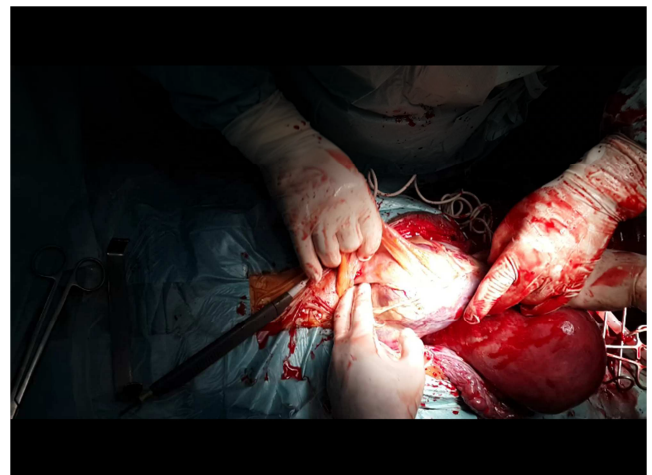


Figure 14. Second pregnancy location.

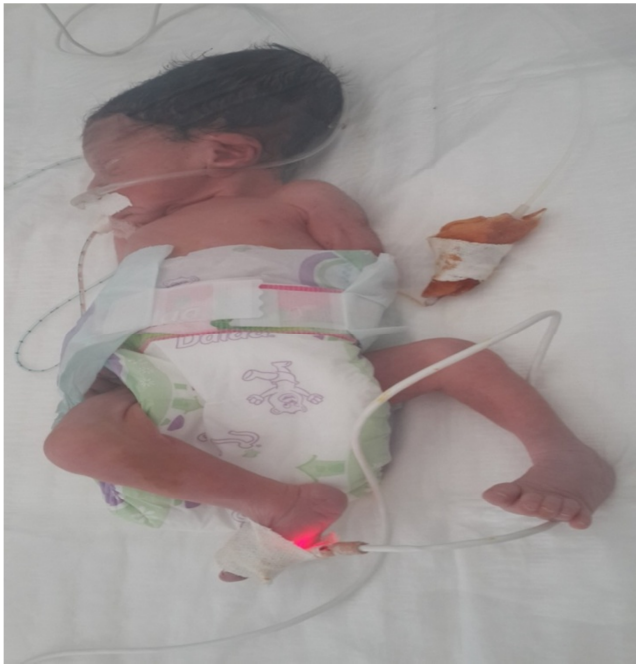

Figure 15. Photo of the second twin.

3. Commentary

Heterotopic pregnancy is the combination of IUP and an EP. The first case was reported by Duvernet in 1708 during an autopsy [1, 2, 4, 5]. Epidemiologically, the frequency of heterotopic pregnancy is variable depending on the series, approximately 1/30,000 in cases of assisted pregnancies [3, 4, 6].

Heterotopic pregnancy is becoming more common due to the increase in sexually transmitted infections, tubal surgery and especially the proliferation of ovulation inducing treatments and modern techniques of in vitro fertilization [1, 3, 6].

Risk factors for heterotopic pregnancy are those of the ectopic pregnancy. Genital infection is the main risk factor, especially sub-acute or chronic infections that go unnoticed. Tubal infertility is also a risk factor. Indeed, modern techniques of in vitro fertilization have greatly changed the epidemiological profile of heterotopic pregnancies [2, 3, 5, 6].

Factors specific to assisted pregnancies increase the risk of heterotopic pregnancy, such as a high rate of transferred embryos, transfer near a uterine horn, excessive pressure on the syringe, transfer difficulties and the presence of sequelae adhesions of endometriosis lesions. Finally, previous surgeries on the abdomen or pelvis are also risk factors.

Patho-physiologically, heterotopic pregnancy can result from simultaneous fertilization or delayed fertilization (fertilization of two ova produced a short interval during the same cycle by sperm from two successive copulations). This hypothesis is discussed in the induction of ovulation when two injections of HCG are administered [3, 4, 6, 7].

Clinically, the classic triad (amenorrhea, vaginal bleeding and pelvic pain) is often found in cases of heterotopic pregnancy. There is often an abdominopelvic pain, paroxysmal episode in early pregnancy followed by a chronic unexplained background pain (figure 15).

Other signs must attract attention: persistent nausea and vomiting, bleeding, anemia, contrasting with the modest nature of bleeding. Sometimes the clinical picture is dominated by gastrointestinal symptoms [2, 4, 5, 6, 7, 8].

However, the diagnosis is difficult if signs of IUP are in the foreground with an array of threatened abortion or miscarriage. This is a rare event; it is serious because the signs of ectopic pregnancy are masked by those of the EP. The unsuspected EP departure will occur the following day by an array of tubal rupture. Therefore, the persistence of bleeding and pelvic pain after a miscarriage, despite uterine vacuity, should suggest heterotopic pregnancy. The diagnosis is sometimes given in support of a massive hemoperitoneum of unknown pregnancy [3, 4, 6, 7, 8, 9].

Finally, heterotopic pregnancy can be totally asymptomatic, discovered incidentally during an early ultrasound; this is the case in over half of cases, according to some authors. Cases of heterotopic pregnancy carried to term with spontaneous pregnancy and birth defects have been reported [4, 5, 7, 10, 11].

Our patient complained of chronic constipation since the beginning of her pregnancy; clinical examination found the upper uterine size for gestational age and the Douglas pouch filled with an abdominal pregnancy [8, 9, 10, 12].

The determination of elevated levels of plasma b-HCG is sometimes evidence of the presence of a second egg when rates between Day 12 and Day 16 are irregularly high with intrauterine single egg appearing, or if rates remain high after the evacuation of intrauterine pregnancy.

Pelvic ultrasound is the main paraclinical examination method for the diagnosis of heterotopic pregnancy [10, 11, 13, 14, 15]. This method determines the precise term of the pregnancy, the quality of the IUP, the position of the ectopic pregnancy and the existence of a possible effusion. Certainly, it is now possible to diagnose potential complications when the diagnosis reveals an intrauterine gestational sac containing an embryo and another bag containing extra-uterine embryonic echoes, especially when there is a cardiac activity is positive. However, ultrasound may be falsely reassuring; it may not clearly show the ectopic pregnancy, or may not be properly interpreted [10, 11, 12, 16].

Numerous publications have demonstrated the decisive contribution of MRI in diagnosis. It shows a fetus in the abdominal cavity circumscribed by the non myometrial tissue, frequently a transverse positioning, oligo or hydramnios. MRI also provides information on the ectopic placental location providing valuable preoperative information. A total or partial insertion into the uterus and hemorrhagic seems a less favorable prognosis for the fetus. It also keeps track of placental involution [12, 16, 17, 18].

Laparoscopy is the gold standard to confirm the diagnosis of heterotopic pregnancy. It allows to clearly determine the size of the uterus, view the EP, assess the state of the trunk, quantify the hemoperitoneum, and achieve therapeutic procedure [3, 12, 13, 15, 18].

The development of heterotopic pregnancy depends on early diagnosis and management. Maternal prognosis is more pejorative than the diagnosis made later.

The treatment of heterotopic pregnancy is intended to remove the EP for maintaining at best the UIG, preserve subsequent fertility of the patient and reduce the risk of recurrence. The treatment may be medical or surgical. Laparotomy is performed less in favor of laparoscopy [16, 18, 19].

Laparotomy is still indicated if hemodynamically unstable. Surgical treatment should strive to be conservative because it is often followed by infertility. In cases of radical treatment, salpingectomy should be performed without resection of the interstitial portion to not weaken the uterus. If a wedge resection of the uterine horn is made, prophylactic cesarean section should be considered [12, 14, 15, 18, 20].

Medical treatment based on local injection of KCl or hyperosmolar glucose solution was also reported under ultrasound guidance and was a good alternative to surgery. Methotrexate local or general injection is not recommended because of its teratogenic and toxic effect on IUP. Surgical treatment, even by laparotomy, does not seem to disrupt the development of the IUP, subject to the manipulation of the uterus is minimal and short-term anesthesia, prophylactic tocolysis is questionable [16, 17, 19, 20].

The diagnosis of advanced abdominal pregnancy with living fetus poses the problem of management [13, 14]. Should we keep the pregnancy? On what criteria? If kept, when should the birth occur? With what tools should we assess and monitor the fetus? How should surgical bleeding risk be managed?

Most authors recommend laparotomy once diagnosed, regardless of fetal status, given the unpredictable and serious nature of maternal complications occurring in any term.

Some authors have proposed a list of criteria required to provide conservative treatment for GA diagnosed after 20 SA [13, 16, 19]:

- absence of malformation;
- no evidence of maternal or fetal decompensation;
- monitoring of fetal well-being;
- in the low insertion placental abdomen: distance of the liver and spleen;
- presence of amniotic fluid around the fetus;
- continuous hospitalization in an appropriate facility;
- informed consent of the patient.

A multidisciplinary study should be conducted including obstetrician, pediatrician, anesthesiologists, closely with the couple duly informed. This discussion will include maternal age, parity, the context of occurrence of pregnancy (long history of infertility, PMA...) diagnostic term clinicopathologic data imaging (fetal morphology, localization of pregnancy website placental insertion), the possibility of access to a medical-surgical structure and adapted reanimation [2, 14, 19, 20].

In practice, if the diagnosis is made before 20 SA, abortion will be discussed, and depart from this attitude must remain exceptional. If a decision conservation pregnancy, hospitalization in a suitable structure until birth is required. The term variable is programmed laparotomy in the literature from 34 to 38 weeks [2, 11, 17, 20].

In its review of the literature colligeant 1161 case of

abdominal pregnancy, Stevens found a 21.4% cumulative rate of malformations and deformations. Deformations in descending order of frequency are: craniofacial asymmetry, joint abnormalities, equinovarus feet, kyphoscoliosis, skin impressions, pulmonary hypoplasia, stiff neck, webbed neck malformations are found cleft palate, limb abnormalities (from strain to amputation), diseases of the central nervous system (myelomeningocele, microcephaly, hydrocephalus, anencephaly). Mechanisms are discussed early vascular insufficiency linked to ectopic pregnancy headquarters explaining malformations, deformations are the result of late mechanical stress. The neonatal survival rates after 30 weeks was 63%. Antenatal fetal monitoring will be performed by regular weekly growth scans with umbilical Doppler and measurement of the amount of amniotic fluid. On each day realize a recording of fetal heart rate [13, 16, 18].

The scheduled 34 SA laparotomy will be carried forward in case of stagnant growth, alteration or Doppler with maternal complication [15, 16, 19].

At laparotomy, performed by a surgical team with skills relevant to risk of bleeding and the possibility of a urinary or gastrointestinal vascular surgery, the problem arises from the high risk of bleeding issue [13, 14, 20].

Three options: rescue practice at laparotomy when feasible, leave the placenta in situ after proximal ligation of the cord and wait for a spontaneous reabsorption monitored by Doppler and b-HCG, or leave the placenta in situ and there add methotrexate. Instead of embolization is very limited on isolated cases in the literature. Placental resorption is slow, secondary complications have been described, but are uncommon (secondary hemorrhage, sub-occlusive syndrome, sepsis, ureteral obstruction, choriocarcinoma) [4, 7, 17, 18, 20].

Breast prognosis is similar to simple ectopic pregnancies, with a mortality of less than 1%. No maternal deaths were reported in the literature after 1983. The risks are surgery and anesthesia, in addition to special risks of laparoscopy in cases of ovarian hyperstimulation [4, 6, 14, 16].

Anemia is the most common complication, sometimes requiring blood transfusions. Subsequent fertility may be compromised permanently or significantly reduced if a hysterectomy must be performed before an uncontrolled bleeding during pregnancy uterine horn, or oophorectomy is necessitated by a very hemorrhagic ovarian pregnancy [11, 12, 15, 16, 19].

4. Conclusion

Advanced heterotopic pregnancy with abdominal localization is a rare form. Its evolution may involve maternal prognosis and prognosis of intrauterine pregnancy. The treatment of choice is the termination of ectopic pregnancy. The decision to continue the pregnancy should be well thought out because the risks are very high and the results are never certain. Certainly the mix of properly used technologies, well trained physicians, and well informed patients must be the norm, even if such cases are extremely rare.

References

- [1] Ludwig. M, Kaisi. M, Bauer. O and Diedrich. K. The forgotten child - a case of heterotopic, intraabdominal and intrauterine pregnancy carried to term. *Human Reproduction* 1999; 5:1372-1374.
- [2] Soo Jeon. H, Jun Shin. H, HeeKim. I and al. A case of spontaneous heterotopic pregnancy Presenting with heart activity of both embryos. *Korean J ObstetGynecol* 2012;55:339-342.
- [3] Montilla. F, Amar. P, Boyer. S and al. Grossesse hétérotopique à propos d'un cas avec un tableau clinique rare. *J GynecolObstetBiolReprod* 2007;36:302-305.
- [4] Ben Temime. R, Mathlouthi. N, Makhoulf. T and al. Heterotopic pregnancy: A seven-case report and review of literature. *Imagerie de la Femme* 2012; 22: 110-116.
- [5] Maheswari. S, Seetha. P. Triplet heterotopic pregnancy following ovulation induction with clomiphene citrate: a case report and review of literature. *Int J Reprod Contracept Obstet Gynecol.* 2013;4:743-745.
- [6] Addar. M. Heterotopic pregnancy following induction of ovulation in PCOS. *Middle East Fertility Society Journal.* 2004; 2: 173-175.
- [7] Wanga. PH, Chaoa. H. T, Tsengb. JY and al. Laparoscopic surgery for heterotopic pregnancies: a case report and a brief review. *European Journal of Obstetrics & Gynecology and Reproductive Biology* 1998;80:267-271.
- [8] Ghandi. S, Ahmadi. R, Fazel. M. Heterotopic pregnancy following induction of ovulation with clomiphene citrate. *Iranian Journal of Reproductive Medicine* 2011; 4: 319-321.
- [9] Ousehal. A, Mamouchi. H, Gazli. M and al. Heterotopic pregnancy: value of transabdominal sonography, a case report. *J Raiol* 2001;82:851-3.
- [10] Avitabile. NC, Kaban. NL, Siadecki. SD and al. Two Cases of Heterotopic Pregnancy Review of the Literature and Sonographic Diagnosis in the Emergency Department. *J Ultrasound Med* 2015; 34:527-530.
- [11] Sharma. JC, Kumar. BP, Talukdar. R. Is heterotopic pregnancy uncommon? *Asian Pac. J. Health Sci.*, 2014; 1: 458-460.
- [12] Nishat. F, Mubarak Al Badi. M, Rahman. M and al. Heterotopic pregnancy with natural conception; a rare event that is still being misdiagnosed: a case report. *Clinical Case Reports* 2016; 4: 272-275.
- [13] Beddock. R, Naepels. P, Gondry. C and al. Diagnostic et concepts actuels de prise en charge de la grossesse abdominale avancée. *GynécologieObstétrique&Fertilité* 2004; 32: 55-61.
- [14] Gbadebo Adesiyun. A, Ayodele-Cole. B. Heterotopic tubal pregnancy with live twin birth complicating ovulation induction assisted cycle. *Open Journal of Obstetrics and Gynecology*, 2012, 2, 325-327.
- [15] Li. J. B, Ling-ZhiKong. LZ, Yang. JB and al. Management of Heterotopic Pregnancy Experience From 1 Tertiary Medical Center. *Medicine* 2016;5,95: e2570.
- [16] Jeon. HS, Hyun-Jun Shin. HJ, Kim. IH and al. A case of spontaneous heterotopic pregnancy. Presenting with heart activity of both embryos. *Korean J ObstetGynecol* 2012;55:339-342.
- [17] Baxi. A, Kaushal. M, Kamarkal. HK and al. Successful expectant management of tubal heterotopic pregnancy. *J Hum ReprodSci* 2010;2:108-110.
- [18] Kartikey. R. Shastri. KR, Anand. NI, Ganatra. BM. A rare case of heterotopic pregnancy in natural conception with ectopic pregnancy. *Indian Journal of Obstetrics and Gynaecology Research* 2015;2:174-175.
- [19] Rawal. S, Koirala. P, Singh. M, Rana. A. Heterotopic pregnancy with spontaneous intrauterine conception: A rare clinical entity with diagnostic dilemma. *Kathmandu University Medical Journal* 2008; 1: 105-108.
- [20] Khediri. Z, Mbarki. CM, Benabdelaziz. A and al. Heterotopic pregnancy in spontaneous Report of three cases and review of literature. *International Journal of Case Reports and Images* 2012; 10: 8-11.