

# Minimally Invasive Hysterectomy for the Large Uterus Using the LigaSure

**Gamal Hassan Eltabbakh<sup>\*</sup>, Samantha Gregoire, Georgia Danine Eltabbakh**

Lake Champlain Gynecologic Oncology, Professional Corporation, South Burlington, the United States

## Email address:

[geltabbakh@lcgo.com](mailto:geltabbakh@lcgo.com) (G. H. Eltabbakh)

<sup>\*</sup>Corresponding author

## To cite this article:

Gamal Hassan Eltabbakh, Samantha Gregoire, Georgia Danine Eltabbakh. Minimally Invasive Hysterectomy for the Large Uterus Using the LigaSure. *Journal of Gynecology and Obstetrics*. Vol. 10, No. 4, 2022, pp. 203-210. doi: 10.11648/j.jgo.20221004.17

**Received:** July 16, 2022; **Accepted:** August 1, 2022; **Published:** August 10, 2022

**Abstract:** Objective: To compare the outcome of patients with uteri > 250 gm who had minimally invasive hysterectomy (MIH) to those who had abdominal hysterectomy (AH) using the LigaSure, stratify complications based on the uterine weight and report follow-up of patients who had vaginal morcellation. Study Design: A retrospective cohort study comparing patients with uteri > 250 gms who underwent vaginal hysterectomy (VH), laparoscopically assisted vaginal hysterectomy (LAVH) and robotic total laparoscopic hysterectomy (RTLH) to those who underwent AH. In both groups the LigaSure was used. Patients who had vaginal morcellation were followed-up. Results: A total of 166 patients were included: 10 patients had VH, 81 patients had LAVH, 22 patients had RTLH, and 53 patients had AH. Six (5%) MIH were converted to AH. Sixty-four percent of patients who needed hysterectomy were able to have successful MIH. Both groups were similar regarding age, American Society of Anesthesiologists score, previous laparotomy, previous C sections, body mass index, estimated blood loss, operative and postoperative complications, and final pathology report. The conversion and complication rates increased with uterine weight > 1000 gm. Patients who had AH had larger uteri and stayed in the hospital longer than those who had MIH. Thirty patients had vaginal morcellation with no consequences. Conclusion: Most patients with a large uterus could have save MIH with shorter hospital stay. Conversion and complications increase for uteri larger than 1000 gm. Vaginal morcellation had no consequences and the use of LigaSure provided adequate hemostasis.

**Keywords:** Hysterectomy, Minimally Invasive, Laparoscopic, Robotic, Uterine Weight, Large Uterus

## 1. Introduction

Hysterectomy is the most common major gynecologic surgery performed in women with over 500,000 performed annually for benign disease in the United States [1, 2]. Symptomatic uterine fibroids are one of the major indications for hysterectomy [1, 2] and a common consequence of uterine fibroids is uterine enlargement.

Nieboer et al. [3] in a randomized study reported that with a follow-up of 4 years, patients who underwent laparoscopic hysterectomy (LH) had a better quality of life compared with AH. The American College of Obstetricians and Gynecologists (ACOG) recommends MIH whenever feasible based on their well-documented advantages over AH [4]. ACOG defines MIH as VH, conventional LH including LAVH and RTLH [4]. Although MIH is recommended, AH

remains an important surgical option for some patients [4].

Factors that govern the choice of the route of hysterectomy include patient's preference, surgeon's experience and preference, availability of equipment, indication for the hysterectomy, size of the uterus, proportion of the size of the uterus to the vaginal capacity, presence of adnexal pathology, adhesions and other factors affecting the pelvic anatomy, need for additional surgery and whether the surgery is performed as an emergency or scheduled [4].

The weight of the uterus had been found to be an independent factor affecting surgical and postoperative outcome [5]. An enlarged uterus limits uterine maneuverability, interferes with visualization of important pelvic structures like ureters and bladder, is often associated with displacement of the uterine or ovarian pedicles, is often associated with increased vascularity, might interfere with placement of the laparoscopic trocars, and presents

challenges in removal following devascularization and detachment from the ligaments [6, 7].

The definition of a large uterus has varied in different studies. Different authors have defined an enlarged uterus as being > 12-week gestation [8], > 16 weeks [9], weighing > 180 gm [10], weighing > 250 gms [11, 12], weighing > 300 gm [13] and weighing > 500 gms [14]. Some authors [15] developed a classification system of enlarged uterus which depends on intraoperative visualization of the uterine and ovarian pedicles and whether they are displaced or not.

Available techniques for removal of a large uterus in MIH include removal through mini laparotomy, uterine morcellation through laparoscopic incisions or vaginal morcellation [16]. The Food and Drug Administration (FDA) issued a warning against the use of laparoscopic power morcellators for fear of dissemination of an unexpected uterine malignancy [17]. Following this warning there has been a decrease in the number of laparoscopic hysterectomies [18].

Because uterine enlargement is often associated with displacement and engorgement of the uterine and ovarian blood supply, securing the vascular pedicles in MIH is important. Reports have investigated the efficacy of LigaSure vessel sealing instrument in MIH and attested to its efficacy [19]. LigaSure uses advanced bipolar electrosurgery and is designed to grasp, seal, and cut and can coagulate vessels up to 7 mm in diameter.

The aim of the current study was to investigate the feasibility and surgical outcome of MIH for women with benign enlarged uteri weighing >250 gm using the LigaSure vessel sealing instrument, to stratify surgical complications and conversion rates based on uterine weight and to investigate the consequences of vaginal morcellation of these uteri.

## 2. Material and Methods

We conducted a retrospective cohort study (Canadian Task Force classification II-2 [20]) of all hysterectomies performed for benign diseases in our practice between January 2011 and January 2021 in which the uterine weight was > 250 gms. Inclusion criteria were normal cervical cytology within a year prior to hysterectomy, benign endometrial biopsy for women with abnormal uterine bleeding or thickened endometrial stripes on pre-operative transvaginal ultrasound, known uterine weight and use of the LigaSure vessel sealing instrument for securing the pedicles. Exclusion criteria included: known or suspected endometrial cancer, or uterine sarcoma, adnexal masses, unknown uterine weight and use of other techniques to secure the pedicles other than the LigaSure.

Identification of patients was achieved through review of our practice electronic medical records. The operative logbooks were reviewed and patients who had the following procedures: VH, AH, TLH, RTLH and LAVH between January 2011 through January 2021 identified. The operative and pathology reports of these patients were reviewed and

patients who had reported uterine weight > 250 gms and no adnexal masses identified. During the period of the study the surgeon performing these surgeries used the LigaSure Maryland vessel sealing instrument in the laparoscopic portion of LAVH and the LigaSure Impact vessel sealing instrument in VH, AH and the vaginal portion of LAVH. Securing the pedicles among women who had RTLH was performed using the bipolar coagulation and monopolar diathermy.

The medical records of all patients were reviewed, and the following information abstracted by one of the co-authors (SG): patient's age, American Society of Anesthesiologists (ASA) scoring system, number or previous laparotomy, number of previous C sections, body mass index (BMI), estimated amount of blood loss (EBL), operative and postoperative complications, length of hospital stay, uterine weight and the final pathology report. Operative and postoperative complications were classified using the Clavien-Dindo classification systems [21]. Patients who needed uterine morcellation were noted and the technique of uterine morcellation reported. These patients were followed up for complications related to uterine morcellation. The patients were divided into two groups: MIH group which included VH, LAVH and RTLH and AH group and both groups compared for characteristics and outcome.

During the study period, our practice recommended MIH for women who needed hysterectomy for a benign enlarged uterus provided that the pre-operative findings predicted successful outcome for MIH (uterine fundus below the umbilicus, no adnexal masses, no changes in the abdominal wall that preclude safe placement of laparoscopic trocars and no suspicion of uterine sarcoma). Patients with known endometrial cancer or atypical complex endometrial hyperplasia were offered MIH as the first choice but were not included in this analysis. Patients with large umbilical hernia, colostomy, uterine fundus above the umbilicus, virginal status and those who refused MIH, had AH.

Pre-operative work-up of all patients included: history and physical, normal cervical cytology within one year of the hysterectomy, pelvic ultrasound, and benign endometrial biopsy for women with abnormal uterine bleeding or abnormally thickened endometrium. Some patients also had computed tomography of the abdomen and pelvis and/ or pelvic magnetic resonance imaging. All patients received pre-operative prophylactic antibiotics and 5000 units of heparin within 30 minutes of the incision. The abdomen was prepped using Chloro-Prep.

Patients who had LAVH had three 5-mm incisions (umbilical or supra-umbilical depending on the size of the uterus) and two lower abdominal quadrant incisions. We used the Pelosi uterine manipulator for all patients. The ovarian pedicles, round ligaments were coagulated and cut laparoscopically using the 5 mm LigaSure (Covidien, Mansfield, MD) Maryland Jaw 37 cm laparoscopic instrument whose tip can rotate 360 degrees. The peritoneum of the utero-vesical pouch was incised, the bladder dissected downwards, and the uterine vessels isolated laparoscopically.

The procedure was then converted to a vaginal approach and the uterosacral ligaments, cardinal ligaments and uterine vessels coagulated and transected using the LigaSure Impact vessel sealing instrument whose tip can rotate 90 degrees. Following removal of the uterus vaginally, a final laparoscopic look was performed to assure hemostasis and absence of retained parts of the uterus if uterine morcellation was performed.

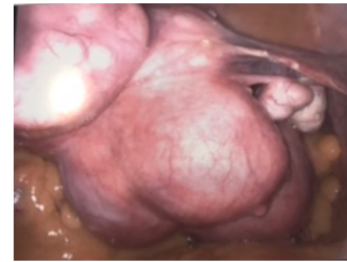
Patients who had VH, had the uterosacral ligaments, cardinal ligaments and uterine vessels coagulated and cut using the LigaSure Impact vessel sealing instrument. If the tubes and ovaries were to be left, their attachment to the uterus were coagulated and cut using the LigaSure Impact vessel sealing instrument.

Patients who had RTLH had the V-care uterine manipulator, had 3 or 4 da Vinci ports placed depending on the anticipated complexity of the surgery and patients' body habitus and had an 8 mm assistant port placed. The camera port was placed in the umbilicus or higher depending on the patient's body habitus and the level of the fundus of the uterus. The other da Vinci ports were placed on either side of the camera port along a line 2 cm higher than the camera port. The assistant port was placed in the right lower quadrant. We used monopolar scissors through arm 1, fenestrated bipolar grasper through arm 2 and the prograsper through arm 3 if used. The ovarian pedicles and uterine vessels were coagulated and cut using bipolar and monopolar diathermy. Following removal of the uterus a final laparoscopic look was done to assure hemostasis and absence of retained parts of the uterus if uterine morcellation was performed. All patients who had LAVH or RTLH, had cystoscopy at the end of the procedure before removing the laparoscopic trocars to ensure bladder and ureteral integrity.

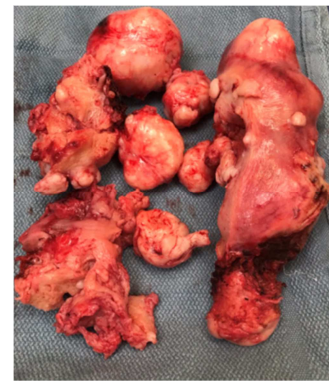Patients who had AH had either Pfannenstiel or midline infraumbilical incision depending on the uterine size, patients' body habitus and presence of previous abdominal scars. The round ligaments, ovarian vessels, uterine ligaments, and vessels were coagulated and cut using the LigaSure Impact vessel sealing instrument. All AH performed were total hysterectomies.

In all MIH, the uterus was delivered vaginally. Patients whose uteri were too big to be delivered intact had controlled uterine morcellation vaginally. We did not use containment bags. After complete separation of the uterus from its pedicles and devascularization, the cervix was grasped with single or multiple tooth tenacula and outward traction performed. A wide Deaver retractor was placed between the separated uterus and the bladder for bladder protection. The long Auvards weighted vaginal retractor was placed in the cu-de-sac between the uterus and the rectum protecting the rectum. Alternatively, we sometimes used narrow or wide Deavers in the cul-de-sac. Right angle vaginal retractors were placed on the sides of the uterus to protect the vaginal walls. The uterus was kept in or outside the vagina until completely removed. We usually started with scalpel amputation of the cervix. If the patient had uterine fibroids, vaginal myomectomy was performed starting from the midline. If the

patient did not have identifiable fibroids, wedge shaped segments were removed from the uterus using the scalpel starting from the midline while maintaining outward traction on the remainder of the uterus with tenacula or Allice clamps and keeping it in or outside the vagina. The procedure was repeated until the remainder of the uterus was small enough to be delivered vaginally. Following removal of the uterus, the uterine pedicles were inspected for hemostasis and the vaginal walls inspected for tears. Figure 1 shows the laparoscopic appearance of one of the study patients and figure 2 shows the same uterus following vaginal morcellation.



**Figure 1.** Laparoscopic appearance of one of the uteri included in the study.



**Figure 2.** Appearance of the same uterus shown in Figure 1 following vaginal morcellation.

Post-operatively, patients were maintained on prophylactic heparin every 12 or 8 hours depending on the patient's risk factors for blood clots. The diet was advanced as fast as tolerated and the intravenous fluids were stopped on postoperative day 1 if patient was tolerating clear liquids. Criteria for patients' discharge included being afebrile, having stable vital signs, ambulating, voiding, tolerating oral diet and being comfortable with oral pain medications. Postoperatively patients were usually seen at 2 weeks and 3 months following surgery then annually.

Statistical analysis was performed using the student t-test and the Mann-Whitney test for comparison of continuous variables and the Pearson  $\chi^2$  for comparison of proportions.  $P < 0.05$  was considered statistically significant.

### 3. Results

Our search identified a total of 166 consecutive patients who fulfilled enrollment criteria. All surgeries were

performed by the same surgeon (GHE). Among the 166 patients 10 patients had VH, 81 patients had LAVH, 22 patients had RTLH, and 53 patients had AH.

Table 1 lists patients' characteristics for each of the study groups. Four VH patients had additional surgeries [cystorectoce repair (2), tension-free vaginal tape (1) and culdoplasty (1)]. Four LAVH patients had additional

surgeries [cystorectoce repair (2), tension-free vaginal tape (1) and umbilical hernia repair (1)] and two of the AH patients had additional surgeries [Burch colposuspension (1) and umbilical hernia repair (1)]. There was no significant difference between the study groups regarding patient's age, ASA, BMI, previous laparotomy, previous C-sections and the percentage of patients who had removal of the adnexa.

**Table 1.** Patients' Characteristics.

	VH	LAVH	RTLH	AH
Number	10	81	22	53
Removal of adnexa:	0	55 (67.9%)	21 (95.5%)	42 (79.2%)
Additional surgeries:	4 (40%)	4 (4%)	0	2 (4%)
Age (years):				
Median (range)	45 (30-52)	48 (34-68)	47 (29-80)	47 (35-75)
= or > 50	3 (30%)	28 (35%)	6 (22%)	27 (51%)
ASA				
Median (range)	2 (1-3)	2 (1-3)	2 (1-3)	2 (1-3)
BMI				
Median (range):	31 (21-67)	32 (20-49)	27 (21-50)	30 (18-51)
= or > 30:	5 (50%)	38 (47%)	8 (36%)	27 (51%)
= or > 40:	2 (20%)	13 (16%)	4 (18%)	11 (21%)
Previous laparotomy:				
Median (range)	0 (0-1)	0 (0-1)	0 (0-1)	0 (0-2)
= or > 2:	0	0	0	1 (2%)
Previous C section				
Median (range):	0 (0-1)	0 (0-3)	0 (0-3)	0 (0-3)
= or > 2:	0	8 (10%)	3 (14%)	8 (15%)

VH: vaginal hysterectomy, LAVH: laparoscopically assisted vaginal hysterectomy, RTLH: robotic total laparoscopic hysterectomy, AH: abdominal hysterectomy.

Table 2 lists the surgical outcome of the different surgical approaches. Six patients who had MIH had the procedure converted to laparotomy [one planned on having RTLH (5%) and 5 planned on having LAVH (6%)]. These 6 patients were kept in the RTLH and LAVH groups when outcome was analyzed. None of the patients planned to have VH were converted to laparotomy. Reasons for conversion to

laparotomy included large uterine size (4), pelvic adhesions precluding visualization of anatomic structures (1) and large uterine size and pelvic adhesions (1). Two of the patients whose procedure was converted to laparotomy had uterine weights of > 1000 gm. There was no significant difference among patients who had different surgical approaches regarding EBL, operative or postoperative complications.

**Table 2.** Surgical Outcome.

	VH	LAVH	RTLH	AH
Conversion to laparotomy:	0	5 (6%)	1 (5%)	-
Estimated Blood loss (mL):				
Median (range)	75 (50-120)	100 (50-900)	75 (50-400)	100 (50-300)
= or > 500	0	1 (1%)	0	0
Uterine weight (gm)				
Median (range):	273 (252-325)	311 (251-1050)	266 (252-560)	550 (251-2940)
= or > 500:	0	24 (30%)	1 (5%)	27 (51%)
= or > 1000:	0	3 (4%)	0	13 (25%)*
Vaginal morcellation:	0	27 (33%)	3 (14%)	-
Operative complications:				
Grade I or II	0	1 (1%)	0	
Grade III	0	0	0	
Postoperative complications:				
Grade I or II	0	2 (2.4%)	1 (5%)	4 (8%)
Grade III	0	1 (1.2%)	2 (9%)	0
Hospital stay: (days)				
Median (range)	1 (1)	1 (1-4)	1 (1-3)	2 (1-4)*
= or > 3:	0	2 (3%)	1 (5%)	9 (17%)

VH: vaginal hysterectomy, LAVH: laparoscopically assisted vaginal hysterectomy, RTLH: robotic total laparoscopic hysterectomy, AH: abdominal hysterectomy. \* Statistically significant.

Table 3 lists the characteristics and outcome of the 6 patients whose procedure was converted from MIH to AH. One of these

6 patients stayed in the hospital for the longest duration among the whole study group (4 days) and one patient had the additional complication of excessive blood loss (900 mL) and was transfused 2 units of packed red blood cells.

**Table 3.** Characteristics and outcome of patients converted to laparotomy.

	Patient #1	Patient #2	Patient #3	Patient #4	Patient #5	Patient #6
Planned surgery:	RTLH	LAVH	LAVH	LAVH	LAVH	LAVH
Age (years):	29	48	53	59	52	47
BMI:	43	30	30	41	27	38
Previous Laparotomy:	1	0	0	0	0	0
Previous C section	3	0	0	0	0	0
Uterine weight (gm)	440	380	285	565	1015	1024
Reason for conversion	Adhesions and uterine size	adhesions	adhesions	Uterine size	Uterine size	Uterine size
Operative complications	0	0	0	0	0	Excessive blood loss
Postoperative complications	0	0	0	0	0	0
Estimated blood loss (mL)	400	200	150	200	200	900
Hospital stay: (days)	1	2	4	3	2	2

RTLH: robotic total laparoscopic hysterectomy, LAVH: laparoscopically assisted vaginal hysterectomy.

Table 4 lists the characteristics and outcome of patients who had MIH (combined in one group) and patients who had AH. There was no significant difference between both groups regarding patients' age, ASA, BMI, previous laparotomy, previous C section and EBL. Approximately 50% of the study group were obese (BMI = or > 30) and 30% were morbidly obese (BMI = or > 40). Patients who had AH had significantly heavier uteri and stayed longer than those who had MIH.

**Table 4.** Characteristics and outcome of patients who had minimally invasive hysterectomy versus those who had abdominal hysterectomy.

	MIH (n= 113)	AH (n= 53)
Age		
Median (range);	48 (29-80)	47 (35-75)
= or > 50:	36 (32%)	27 (51%)
ASA		
Median (range)	2 (1-3)	2 (1-3)
BMI		
Median (range);	30 (20-50)	30 (18-50)
= or > 30:	56 (50%)	27 (51%)
= or > 40:	26 (23%)	9 (17%)
Previous laparotomy		
Median (range)	0 (0-1)	0 (0-2)
= or > 2:	0	1 (2%)
Previous C section		
Median (range)	0 (0-3)	0 (0-3)
= or > 2:	11 (10%)	8 (15%)
Operative complications	1 (1%)	0
Postoperative complications	6 (5%)	4 (8%)
Estimated blood loss		
Median (range):	100 (50-900)	100 (50-300)
= or > 500:	1 (1%)	0
Uterine weight		
Median (range):	290 (251-1050)	550 (251-2940)*
= or > 500	25 (22%)	27 (51%)
= or > 1000:	2 (2%)	13 (25%)
Hospital stay: (days)		
Median (range)	1 (1-4)	2 (1-4)*
= or > 3	3 (3%)	9 (17%)

MIH: minimally invasive hysterectomy. AH: abdominal hysterectomy. \* Statistically significant.

Table 5 lists conversion rates and complications stratified based on uterine weight among women who had MIH.

Patients who had uterine weight equal to or more than 1000 gm had significantly higher rate of conversion (67%) and complications (33%) compared with patients with lighter uteri.

None of the VH patients had operative or postoperative complications. Among the LAVH patients, one patient had the operative complication of excessive blood loss and was transfused two units of packed red blood cells (Grade II complication), 3 patients had postoperative complications [small bowel obstruction managed conservatively (Grade II, 1), urinary tract infection (Grade II, 1), left ureteral injury managed with sent placement (Grade IIb, 1)]. Among the RTLH patients, 3 patients had postoperative complications [small bowel obstruction managed conservatively (Grade II, 1), pelvic abscess managed with computed tomography guided drain placement (Grade IIIa, 1), and right ureteral injury managed with uroteroneocystotomy (Grade IIb, 1)]. Among the AH patients, 4 patients had postoperative complications [Atrial fibrillation (Grade II, 1), postoperative ileus (Grade II, 1), urinary tract infection (Grade II, 1) and wound infection (Grade II, 1)]. None of the patients developed Grade IV or V complications.

The LigaSure was used to secure ligaments and vascular pedicles in a total of 144 patients (10 VH, 81 LAVH and 53 AH). Only one of these patients (0.7%) had excessive blood loss (900 cc) or significant drop in the postoperative hematocrit. This patient also had the procedure converted from LAVH to AH because of uterine size and adhesions.

Controlled vaginal morcellation was performed in 30 patients [LAVH (27) and RTLH (3)]. None of the VH or AH patients needed morcellation. The final pathology report of the study patients included: uterine fibroids (153), uterine adenomyosis (47), adenomyoma (11) and smooth muscle tumor of unknown malignant potential (STUMP, 1). The median length of follow-up of the study group was 5 years (range 10 months- 10 years). None of the patients had unexpected uterine malignancy in the final pathology report and none of the patients developed disseminated leiomyomatosis. The patient who had the STUMP was 45 years old, had RTLH, her uterine weight was 256 gm and

was delivered vaginally intact. She was followed up for 5 years after the hysterectomy and did not develop recurrence.

**Table 5.** Conversion, operative and postoperative complications stratified based on uterine weight among minimally invasive hysterectomy.

Uterine weight (gm)	Number of patients	Converted to laparotomy	Operative or postoperative complications
251-500	90	3 (3.3%)	5 (5.5%)
501-999	20	1 (5%)	1 (5%)
= or > 1000	3	2 (67%)	1 (33%) *

Statistically significant.

## 4. Discussion

In a nationwide survey, most gynecologists in the United States indicated that their preferred mode of hysterectomy for themselves or their spouses was VH followed by LH. Only 8% of respondents chose AH. Forty-three percent of respondents indicated that they desired to increase their rate of VH and 53% indicated that they desired to increase their rate of TLH. Large uterus was cited as one of the significant barriers to MIH [22].

Our finding about MIH for the large uterus agrees with the findings of other authors [9-11]. Though the number was small, the best surgical outcome was achieved in our VH patients. This is confirmatory of the ACOG recommendation for VH whenever possible [4]. Though large uterine size was considered one of the contraindications for VH by some authors [22], other authors attested to the feasibility and safety of VH among women with large uteri [10]. Though we did not have large number of women with uteri > 1000 gm, our study pointed to a possible limitation of MIH for this group as we had a high conversion rate (67%) and high complication rate (33%). We feel that patients with uteri >1000 gm might be managed safely with planned AH. The fact that in our study more patients with uteri larger than 1000 gm had planned AH than MIH, points to pre-operative preference of AH to women with uteri of this size in our practice. Louie *et al.* [5] demonstrated that the incidence of complications increased as the weight of the uterus increased. Uccella *et al.* [6] and Silas *et al.* [7] reported that LH represented a possibility even in cases of uteri > 1000 gm and that in a dedicated setting with high endoscopic experience, conversion and complications appeared acceptable.

Two of our patients had delayed ureteral injury requiring further surgery. In one of these two patients, the LigaSure was used and in the other patient bipolar and monopolar diathermy were used. It is possible that these injuries were thermal injuries from use of the LigaSure or the diathermy. Thermal injury is a potential complication of all techniques used in MIH for securing the pedicles [23, 24]. The degree of lateral thermal spread depends on the type of instrument, the power settings, and the duration of application [25]. The spread of thermal injury tends to be less with the LigaSure than with monopolar diathermy [23, 24]. The incidence of ureteral injury among our patients was 2/144 (1.4%) is still within the reported ureteral complication rates among women who have LH [7, 26]. A Cochrane database systematic review found more urinary tract injuries in the LH group

compared with AH (odds ratio 2.4) [25]. Silas *et al.* [7] reported that one of 30 patients (3.3%) who had RTLH for uteri > 1000 gm developed postoperative complication of ureteral injury.

In 30 of our patients, we used controlled vaginal morcellation for removal of the uterus. This technique had been described since at least the 1960's [27, 28]. Similar technique was recently described [6, 7]. Other available techniques for reducing the size of the uterus include vaginal morcellation inside a bag, morcellation through mini laparotomy or a laparoscopic trocar inside a bag, scalpel morcellation through mini laparotomy, use of diathermy to bivalve the uterus following its devascularization and detachment from ligaments and intracorporeal myomectomy [6, 16, 29]. Though containment bags might provide some safety, they might leak or break [30].

Vaginal morcellation without a bag carries a very small risk of disseminating an unexpected malignancy and development of leiomyomatosis [16, 31]. The risk of unexpected leiomyosarcoma ranges from 1 in 770 to less than 1 in 1000 surgeries performed for symptomatic leiomyomas [16]. Siedhoff *et al.* [32] performed decision analysis of risk of death from LH with morcellation versus AH for presumed fibroids in premenopausal women. These authors predicted fewer overall death with LH compared with AH. The risk of leiomyosarcoma morcellation was balanced by procedure-related complications associated with laparotomy, including death [32]. To avoid these potential complications, we depended on pre-operative risk stratification, performing the uterine morcellation entirely inside or outside the vagina and performing a final laparoscopic look following removal of the uterus to assure that there were no fragments of the uterus left behind.

Techniques that might help in MIH for the large uterus include: using a uterine manipulator to help uterine maneuverability, using an epigastric portal entry, use of additional trocars, rotating the camera between different trocars for better visualization, use of 30 degree camera up or down depending on the situation, use of hemoclips for individual large vessels, avoiding the use of monopolar diathermy, use of laparoscopic instruments that dissect, grasp, coagulate and cut at the same time to reduce instrument traffic, use of LigaSure vessel sealing instrument as they allow coagulation of larger vessels than Harmonic scalpel or monopolar diathermy [24], use of smoke evacuators, realizing that the tips of laparoscopic sealing instruments get hot after use and avoiding holding delicate tissues when the tip is hot [23], realizing that the uterovesical

peritoneal reflection might be higher than usual among patients having vaginal hysterectomy especially those with cervical or lower uterine segment fibroids and performing intracorporeal myomectomy after devascularization of the uterus and before its removal [6, 7]. Pre-operative use of gonadotrophic hormones agonists might decrease the size of fibroids and allow MIH in some patients who might have had AH [33].

Areas of strength of our study include defined reproducible criteria for uterine enlargement, including patients who had different forms of MIH, having a control group of patients who had AH, standardized pre-operative and postoperative management, standardized surgical techniques and a long follow-up. Areas of weakness include its retrospective nature, depending on our practice medical records for extracting patients' data and small number of patients who had VH and RTLH. The retrospective nature of this study might underestimate postoperative complications as some patients might have presented for their postoperative complications with other providers. Lack of review of hospital operative records precluded assessment of operative times. Having one surgeon could be an area of strength in that the surgical techniques were standardized for all patients. It could also be an area of weakness when applying the findings of the current study to the general population of gynecologists who might vary in their experience with MIH.

Our study shows that most patients who had a benign enlarged uterus could have successful MIH with acceptable complications and short hospital stay. It also shows that laparotomy remains an important approach for women with huge uteri and that the complications of AH are acceptable though the length of hospital stay is longer than with MIH. Though we did not have a control group for patients who had surgery with other techniques than the LigaSure, the low estimated blood loss among our patients and the absence of postoperative bleeding complications point to the efficacy of LigaSure in securing the pedicles. Our study shows that controlled vaginal morcellation among women who had pre-operative screening to decrease the chance of having unexpected uterine malignancy is probably safe.

## 5. Conclusion

Most patients with a large uterus could have save MIH with shorter hospital stay. Conversion and complications increase for uteri larger than 1000 gm. Vaginal morcellation had no consequences and the use of LigaSure provided adequate hemostasis.

## References

- [1] Wu JM, Wechter ME, Geller EJ, Nguyen TV, Visco AG. Hysterectomy rates in the United States, 2003. *Obstet Gynecol* 2007; 110: 1091-5.
- [2] Merrill RM. Hysterectomy surveillance in the United States, 1997 through 2005. *Med Sci Monit* 2008; 14: CR24-31.
- [3] Nieboer TE, Hendricks JC, Bongers MY, Vierhout ME, Kluivers KB. Quality of life after laparoscopic and abdominal hysterectomy. A randomized controlled trial. *Obstet Gynecol* 2012; 119 (1): 85-91.
- [4] ACOG Committee Opinion No. 701: Choosing the route of hysterectomy for benign disease. *Obstet Gynecol* 2017; 129: e155-9.
- [5] Louie M, Strassle PD, Moulder JK, Dizon AM, Schiff LD, VCarey ET. Uterine weight and complications after abdominal, laparoscopic and vaginal hysterectomy. *Am J Obstet Gynecol* 2018; 219 (5): 480-8.
- [6] Uccella S, Cromi A, Serati M, Casarin J, Sturla D, Ghezzi F. Laparoscopic hysterectomy in case of uteri weighing > 1 kilogram: A series of 71 cases and review of the literature. *JMIG* 2014; 21: 460-5.
- [7] Silas DA, Gallo T, Silasi M, Mederes G, Azodi M. Robotic versus abdominal hysterectomy for very large uteri. *JSL* 2013; 17: 400-6.
- [8] Schmidtt JO, Baker MV, Occhino JA, McGee ME, Weaver AL, Bakkum-Games J, Dowdy DC, Pasupathy KS, Gebhart JB. Prospective implementation and evaluation of a decision-tree algorithm for route of hysterectomy. *Obstet Gynecol* 2020; 1345 (4): 761-9.
- [9] Sinha R, Bana R, Sanjay M. Comparison of robotic and laparoscopic hysterectomy for the large uterus. *JSJS* 2019; 23 (1): 1-7.
- [10] Doucette RC, Sharp HT, Alder SC. Challenging generally accepted contraindications to vaginal hysterectomy. *Am J Obstet Gynecol* 2001; 184 (7): 1386-91.
- [11] Emery SL, Boulvain M, Petignat P, Dubuisson J. Operative complications, and outcome comparing small and large uterine weight in case of laparoscopic hysterectomy for a benign indication. *Front in Surg* 2021; 8: 1-6.
- [12] Mistrangelo E, Febo G, Ferrero B, Ferrero S, Deltetto F, Camanni M. Safety, and efficacy of vaginal hysterectomy in the large uterus with the LigaSure bipolar diathermy system. *Am J Obstet Gynecol* 2008; 199 (5): 475-80.
- [13] Bicer M, Guner Z, Karas C, Guclu A, Gol M. Using the LigaSure vessel sealing device in the large uterus at laparoscopic hysterectomy. *Clin Exp Obstet Gynecol* 2016; 43 (6): 880-2.
- [14] Smorgick N, Dalton VK, Patzkowsky KE, Hoffman MR, Advincula AP, As-Sanie S, Comparison of 2 minimally invasive routes for hysterectomy of large uteri. *Int J Gynecol Obstet* 2103; 122: 128-31.
- [15] Uccella S, Kho RM, Garzon S, Casarin J, Zorazato PC, C-Ghezi F. The large uterus classification system: A prospective observational study. *BJOG* 2021; 128: 1626-33.
- [16] ACOG Committee Opinion No. 822. Uterine morcellation for presumed leiomyomas. *Obstet Gynecol* 2021; 137 (3): e63-e74.
- [17] U.S. Food and Drug Administration. UPDATED laparoscopic uterine power morcellation in hysterectomy and myomectomy: FDA safety communication [archived]. Silver Spring (MD): FDA; 2014. Available at <https://wayback.archiveit.org/7993/2070404182209/https://www.fda.gov/MedicalDevices/Safety/AlertandNotices/ucm42443.htm>. Retrived November 5, 2018.



- [18] Ottarsdottir H, Cohen SL, Cox M, Vitonis A, Einarsson JI. Trends in mode of hysterectomy after the U.S. Food and Drug Administration power morcellation advisory. *Obstet Gynecol* 2017; 129: 1014-21.
- [19] Hefni MA, Bhaumik J, El-Toukhy T, Kho P, Wong I, Abdel-Razik T, Davies AE. Safety and efficacy of using the LigaSure vessel sealing system for securing the pedicles in vaginal hysterectomy: randomized controlled trial. *BJOG* 2005; 112 (3): -329-33.
- [20] Tuland T, Balayla J. Study designs and the use of the Canadian Task Force classification. *J Obstet Gynaecol Can* 2018; 40 (11): 1383-4.
- [21] Dindo D, Demartines N, Clavien PA. Classification of surgical complications. A new proposal with evaluation in a cohort of 6336 patients and results of a survey. *Ann Surg* 2004; 240 (2): 205-013.
- [22] Einarsson JI, Matteson KA, Schulkin J, Chavan NR, Sangi-Haghpeykar H. Minimally invasive hysterectomies- A survey on attitudes and barriers among practicing gynecologists. *J Minim Invasive Gynecol* 2010; 17 (2): 167-175.
- [23] Druzijanic N, Pogorelec Zm Perko Z, Mrklic I, Tomic S. Comparison of lateral thermal damage of the human peritoneum using monopolar diathermy, Harmonic scalpel and LigaSure. *Can J Surg* 2021; 55 (5): 317-21.
- [24] Lyons SD, Law KSK. Laparoscopic vessel sealing technologies. *J Minim Invasive Gynecol* 2013; 20: 301-7.
- [25] Diamantis T, Gialikaris S, Kontos M, et al. Comparison of safety and efficacy of ultrasonic and bipolar thermal energy: an experimental study. *Surg Laparosc Endosco Percutan Tech* 2008, 18: 384-90.
- [26] Aarts JWM, Nieboer TE, Johnson N, Tavender E, Gary R, Willem B, Mol B, Kluivers KB. Surgical approach to hysterectomy for benign gynecological disease. *Cochrane Database of Systematic Reviews* 2015; 8. Art. No.: CD003677. DOI: 10.1002/14651858.CD003677.pub5.
- [27] Pratt JH, Gunnalaugsson GH. Vaginal hysterectomy by morcellation. *Mayo Clinic Proc* 1970; 45: 374-87.
- [28] Falcone T, Stovall TG. Hysterectomy, In Berek JS, editor. *Berek & Novak's gynecology*. 15<sup>th</sup> ed. Philadelphia (PA): Wolters Kluwer; 2012. P. 203-42.
- [29] Hong MK, Wei YC, Chu TY, Wang JH, Ding DC. Safety and efficacy of contained manual morcellation during laparoscopic or robotic gynecological surgery. *Int J Gynaecol Obstet* 2020; 148: 168-73.
- [30] Cohen SL, Morris SN, Brown DN, Greenberg JA, Walsh BW, Gargiulo AR, et al. Contained tissue extraction using power morcellation: prospective evaluation of leakage parameters. *Am J Obstet Gynecol* 2016; 214: 257. e1-7.
- [31] Ramos A, Fader AN, Roche KL. Surgical cytoreduction for disseminated benign disease after open power uterine morcellation. *Obstet Gynecol* 2015; 125: 99-102.
- [32] Siedhoff MT, Wheeler SB, Rutstein SE, Geller EJ, Doll KM, WU JM, Clark-Pearson DL. Laparoscopic hysterectomy with morcellation versus abdominal hysterectomy for presumed fibroids in premenopausal women: a decision analysis. *Am J Obstet Gynecol* 2105; 212 (5): e591-8.
- [33] Crosignani PG, Vercellini P, Meschia M, Oldani T, Bramante T. GnRH agnostic before surgery for uterine leiomyomas. Review. *J Reprod Med* 1966; 41 (6): 415-21.